

# **Hollows and folds of the body**

by  
David Mead

2017

**Sulang Language Data and Working Papers:  
Topics in Lexicography, no. 31**



Sulawesi Language Alliance  
<http://sulang.org/>

## LANGUAGES

Language of materials : English

## DESCRIPTION/ABSTRACT

In this paper I discuss certain hollows, notches, and folds of the surface anatomy of the human body, features which might otherwise go overlooked in your lexicographical research. Along the way I also mention names for wrinkles of the face and fold lines of the hands.

## TABLE OF CONTENTS

Head; Face; Neck, chest, and abdomen; Back and buttocks; Arms and hands; Legs and feet; References; Appendix: Bones of the body.

## VERSION HISTORY

Version 2 [29 May 2017] Edits to 'fontanelle' and 'straie,' order of references and appendix reversed, minor edits to appendix.  
Version 1 [15 May 2017] Drafted September 2010, revised June 2013, revised for publication May 2017.

© 2017 by David Mead.

Text is licensed under terms of the Creative Commons [Attribution-ShareAlike 4.0 International](https://creativecommons.org/licenses/by-sa/4.0/) license. Images are licensed as individually noted.

# Hollows and folds of the body

by  
David Mead

*Who has measured the waters in the hollow of his hand,  
or with the breadth of his hand marked off the heavens?*  
Isaiah 40:12

Names for the parts of the human body are universal to human language. In fact names for salient body parts are considered part of the basic or core vocabulary of a language, and are often some of the first words elicited when learning a language.

In this paper I want to raise your awareness concerning certain less salient features of the surface anatomy of the body that may otherwise go overlooked in your lexicography research. Namely, I discuss certain hollows, notches, and folds of the body. You could think of the armpit as one such space. There is also the place that in English we colloquially call the ‘back of the knee,’ but few English speakers know a more exact term for it. Beyond that, what other hollows and notches are there? Along the way I also mention fold lines of the hand and wrinkles of the face.

The following is a checklist which gives terms in both English and Indonesian, along with brief descriptions so that you can easily locate these places. I have sought to provide as full a list as possible, knowing it is unlikely that local languages will have names for *all* of them.

## Head

**1.** fontanelle, the soft spot on top of a baby’s head later closed by bone = *ubun-ubun*, *bagian lunak di atas kepala bayi*. Indonesian *ubun-ubun* can also refer to the crown of the head (e.g. of adults), but check—the local language may have different words. The fontanelle may have spiritual significance; for example it may be regarded as the place where one’s vital spirit (Indonesian: *semangat*) resides, or a point of vulnerability where spirits may enter a young child.

While discussing the tops of people’s heads, you may also wish to elicit the term for ‘hair whorl, cowlick,’ the point or axis on the back of the head around which hairs change direction = *unyeng-unyeng*, *pusaran rambut di atas kepala*.

**2.** nuchal furrow, median nuchal furrow, hollow of the occiput = *lekuk tengkuk*. Occiput is a fancy word meaning back of the head. The hollow of the occiput is the depression on the nape of the neck just below the base of the skull (or technically, just below the external

occipital protuberance). Do not call this the ‘hollow of the neck,’ which refers to a different depression (see below no. 22).

In the Uma language of Sulawesi, the hollow of the occiput is called *pongko'*, and it is a symbol of stinginess. “An Uma doesn’t have to say out loud, ‘Boy, is this guy stingy!’ He just reaches around to the back of his own neck and rubs that hollow spot. Everyone knows what he means” (Michael Martens 2010:pers.comm.).

**3.** parotid notch= *lekuk di belakang telinga dan rahang*. This is the hollow or notch located just behind and below the ear, where the jaw (mandible) meets up with the skull.

**4.** temporal fossa, hollow of the temple = *lekuk pelipis*. The expressions ‘hollow temples’ and ‘hollowing of the temples’ refers to this area becoming more prominent due to aging and loss of the fat pad that underlies the skin in the temple area.

## Face

I treat the face separately because of its salience in human experience, giving particular attention to certain lines or wrinkles, a number of which become more prominent with age. See the picture on the following page.

**5.** transverse frontal sulci, forehead lines, worry lines, lines or wrinkles on the forehead = *keriput dahi, kerutan halus pada dahi, garis-garis halus pada dahi*.

**6.** glabellar lines, furrows on the brow, lines appearing between the eyebrows when the brow is furrowed = *kerutan kening, kerutan yang muncul di antara alis saat mengerutkan dahi*. These furrows are also called frown lines.

**7.** nasal scrunch, bunny lines, horizontal creases that form on the sides of the upper nose when a person smiles or laughs = *kerutan di sisi hidung yang muncul saat senyum atau tertawa*. Not everyone has bunny lines, although they may develop with age. The name bunny lines comes from the perceived similarity with a rabbit wrinkling its nose.

**8.** periorbital lines, optic facial sulci, crow’s feet = *keriput pojok mata, kerutan halus atau garis-garis di pojok mata*. Periorbital lines, colloquially called ‘crow’s feet’ in English, are wrinkles that extend from the outer corners of the eyes.

**9.** nasojugal grooves, wrinkles below the eye, tear troughs = *keriput di bawah mata*. Nasojugal grooves are lines or wrinkles that form where the lower eyelid meets the

cheek.<sup>1</sup> Because they run from the inner corner of the eye out toward the side of the face, these wrinkles are colloquially referred to as ‘tear troughs’ in English.

**10.** labial commissure, corner of the mouth = *pojok mulut*.

**11.** melolabial folds, oral commissures, marionette lines, puppet lines = *garis-garis di pojok mulut*. Melolabial folds are the lines that extend outward, often drooping, from the corners of the mouth when the face is in repose. Colloquially they are called marionette lines or puppet lines in English. Although these lines can give the appearance that one’s mouth is frowning, the term ‘frown lines’ more properly applies to wrinkles on the brow (see above no. 6).



5. forehead lines

6. glabellar lines

7. bunny lines

8. crow’s feet

9. tear troughs

12. lipstick lines

13. crease of the upper lip

14. smile line

15. labiomental crease

16. accordion lines

“Old Woman of Hoi An” © 2004 by Shaun Martin, used by permission

**12.** perioral lines, smoker’s lines, lipstick lines = *keriput bibir atas*. These are wrinkles that extend vertically from the upper lip. They are also called smoker’s lines (because smoking is believed to be a cause) or lipstick lines (because lipstick sometimes bleeds into these small fissures).

<sup>1</sup> Don’t confuse these wrinkles with the conditions called dark circles under the eyes (*lingkaran gelap / hitam di bawah mata*), puffy eyes or bags under the eyes (*mata bengkak, mata gembung, and kantung mata*), and malar mounds, malar bags, or festoons (*kantung di tonjolan tulang pipi*).

When investigating this area of the face, you may also want to elicit the term for ‘milia,’ small white bumps that are sometimes found around the eyes (*bintil-bintil kecil berwarna putih yg muncul di daerah sekitar mata dan pipi*). Milia are keratin-filled cysts that form at the base of hair follicles or in sweat glands, and are not painful or itchy. A single cyst is called a milium.

**13.** philtrum, infranasal depression, crease of the upper lip = *lekukan antara hidung dan bibir atas*. The philtrum is the small cleft or depression that extends from the septum of the nose to the upper lip. It is sometimes colloquially referred to as the crease of the upper lip or simply lip crease. In Uma the term for this depression is *halu' wiwi*, literally 'river of the lips' (Michael Martens 2010:pers.comm.).

**14.** nasolabial folds, nasal-labial folds, smile lines, laugh lines = *garis-garis pada hidung hingga mulut*. Nasolabial folds, colloquially known as 'smile lines' or 'laugh lines,' are facial lines that extend from the wing of the nose to the side of the mouth. Sometimes they curve around slightly under the lower lip, looking like a pair of parentheses. In some people the nasal-labial fold is a fine line; in others it is a deep fold with a pouch of skin hanging over it. Smile lines are not the same as cheek dimples (see below no. 17).

**15.** labiomental crease = *keriput antara bibir bawah dan dagu*. The labiomental crease appears as a horizontal line or wrinkle between the lower lip and the chin.

**16.** accordion lines = *keriput pipi*. In the cosmetic surgery industry, the term 'accordion lines' is reserved for the static, vertical wrinkles which persist on the lower cheek beside the mouth—although smiling accentuates these lines. In younger people, similar lines may appear dynamically when a person is smiling, but disappear when the face is in repose. The name comes from the similarity to the pleats of an accordion.

**17.** dimple (of the cheek), *gelasin* = *lesung pipi, lesung pipit, lesung-lesung*. Some individuals have permanent dimples, in others dimples only appear when they speak or smile.



Girl with dimples. © 2006 by C. Szeto. Licensed under the Creative Commons [Attribution 2.0 Generic](https://creativecommons.org/licenses/by/2.0/) license.

**18.** chin cleft, chin dimple = *dagu belah*. A chin dimple is a vertical fissure on the chin that is present in some individuals.<sup>2</sup>

---

<sup>2</sup> When my children Jonathan and Lydia were younger, they came up with their own name for this feature. They called it a 'butt chin.'

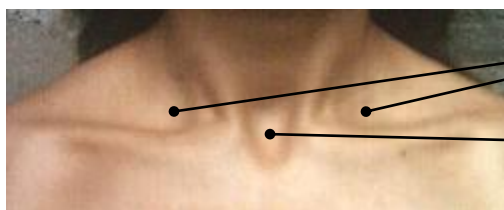
**19.** double chin = *dagu berganda*, *dagu berlapis-lapis*, *lipatan leher*. Another kind of fold is the roll of fat which in some people sags down and creates a wrinkle below the chin, giving the appearance that a person has a second chin.<sup>3</sup>

**20.** jowl, the lower part of a person's cheek, especially one that droops = *pipi mengendur*, *pipi bagian bawah yg mengendur*.

## Neck, chest, and abdomen

**21.** anterior triangle of the neck = *segitiga leher*. This is the region you reach for when you want to feel for a pulse from the carotid artery. The bottom edge of the lower jaw (mandible) forms the top edge of this 'triangle.'

**22.** suprasternal notch, suprasternal depression, jugular notch, hollow of the neck = *lekuk tenggorokan*. This is the depression centered just above the breastbone. It is also called the jugular notch, and colloquially known as the hollow of the throat or the hollow of the neck. If you insert your finger into this notch and push downward, you will find yourself choking.



23. clavicular notches

22. suprasternal notch

© 2006 by Prince of Sarras. Licensed under the Creative Commons Attribution-ShareAlike 3.0 Unported license.

**23.** supraclavicular fossa, clavicular notch(es), hollows just above the collar bone = *lekuk selangka*, *kedua lekuk kiri kanan dekat (di atas) tulang selangka*. A person has two clavicular notches, one on the left and one on the right, which are separated by the suprasternal notch. The tendon which can be seen and felt between the clavicular notch and the suprasternal notch is the lower end of the sternomastoid muscle.

Michael Martens (2010:pers.comm.) reports that the term *lologi* (Ledo, Moma, Lindu; in Uma just *logi*) refers to the clavicular notch, while the collarbone itself is known as the 'bone of the *lologi*.' In folk conception the clavicular notches are regarded to be more prominent in skinny people. Ledo for example has an expression about being 'able to draw water from one's *lologi* (clavicular notch),' meaning a person is so thin that their clavicular notches are like wells that one can draw water from (Donna Evans 2010:pers.comm.).

---

<sup>3</sup> Loose skin which hangs below the chin (*lipatan kulit longgar yang tergantung dari leher*), as in certain breeds of dogs, cattle, etc., is called a dewlap.

In Uma, to poke at a friend's clavicular notch is to tease him or her (*mpolongi*) (Michael Martens 2010:pers.comm.) In Mori Bawah *wengke-wengke* refers to the clavicular notches, while the corresponding stative verb *mewengke-wengke* means 'stingy.'

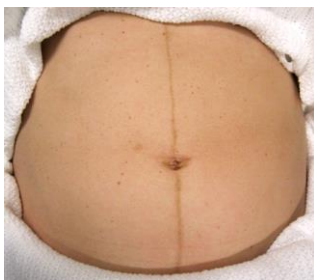
**24.** epigastric fossa, infrasternal depression, substernal notch = *lekuk dada, hulu hati*. This is the depression just below the sternum (breastbone). It lies directly over a cartilaginous extension of the lower sternum known as the xiphoid process (*tulang sudu hati, tulang hulu hati, tulang caping*).<sup>4</sup>

In the Ledo language of Sulawesi, the term for the substernal notch is *bui*, and people talk about a 'fallen *bui*' as a bad sign indicating a severe, wasting disease, usually fatal. When someone thinks their own *bui* is sunken they will assume that they are dying (Donna Evans 2010:pers.comm.).

**25.** abdominal crease, belly fold = *lipatan perut*. This crease is located just below the belly, where the abdomen meets the groin. It is more noticeable when there is excess fat and skin. Rolls or folds of fat on the belly can be referred to as *lipatan lemak di perut*.

**26.** striae (singular: stria), pregnancy stretch marks = *garis-garis atau guratan yang timbul pada perut, paha dsb saat hamil*. Stretch marks are a kind of scarring of the skin that are most often associated with rapid weight gain during pregnancy (but they can also occur on obese individuals, male or female). Striae initially appear as irregular but generally parallel reddish or purple lines, for which reason they are colloquially referred to as 'tiger stripes' in English. Besides the belly, stretch marks can also occur on the breasts, thighs or buttocks. Stretch marks associated with pregnancy are specifically called *striae gravidarum*.

**27.** linea nigra = *garis hitam di tengah perut saat hamil*. Linea nigra is a dark vertical line that appears along the midline of the belly in about three-quarters of pregnancies. It is caused by increased hormonal activity, and usually disappears within a few months after delivery.



Linea nigra in a pregnant woman. © 2012 by James Heilman MD. Licensed under the Creative Commons [Attribution-ShareAlike 3.0 Unported](https://creativecommons.org/licenses/by-sa/3.0/) license.

<sup>4</sup> Do *not* refer to this notch as the 'hollow of the chest,' as this expression has a different meaning, namely the chest cavity where the lungs, heart, etc. are located. There is also a deformity known as 'hollow chest,' 'concave chest' or 'chest concavity' (pectus excavatum), but that is not what we are referring to here.



28. lap = *pangku, pangkuan*.

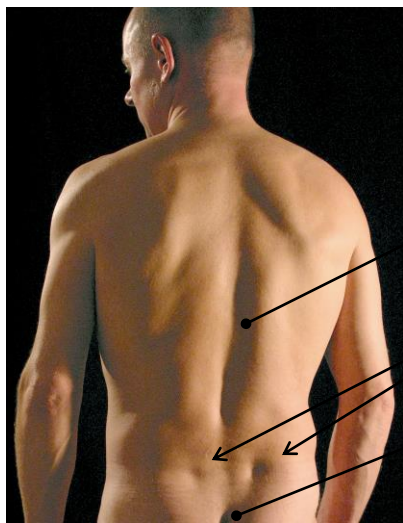
## Back and buttocks

29. posterior median furrow, vertebral furrow, midline furrow down the back = *lekukan tulang belakang*. This is the long vertical depression along the spine from the nape to the tailbone. Scrunching your shoulder blades together deepens this furrow, while bending over makes it lessen or even disappear.

In the bottom of this furrow bony knobs can be felt and seen. These are the tips of the spinous processes of one's vertebrae = *proccus spinosus, penonjolan dari ruas tulang punggung*.

30. lateral lumbar indentations (Indonesian unknown). These indentations are colloquially known as back dimples, butt dimples or (especially on women) dimples of Venus. They are located on the sides of the lower back just above the curve of the tailbone. They are more likely to be seen on thin or trim individuals, as they are easily hidden by fat buildup.

31. intergluteal cleft, crease of the buttocks = *belahan bokong*. This is the groove or crease which separates the left and right cheeks of the buttocks. It is also known as the natal cleft, the gluteal cleft and the vertical gluteal crease, and colloquially as the butt crack (or arse crack). A bawdy Indonesian term is *celah pantat*.



Public Domain (Pixabay)

29. posterior median furrow

30. lateral lumbar indentations

31. intergluteal cleft

32. sacral dimple, pilonidal dimple = *cekungan kulit di sakrum*. A sacral dimple is a small pit or sinus in the area just above the crease of the buttocks. A sacral dimple is a congenital condition which occurs in about two percent of newborns.

## Arms and hands

33. armpit, axilla = *ketiak, kelek*.

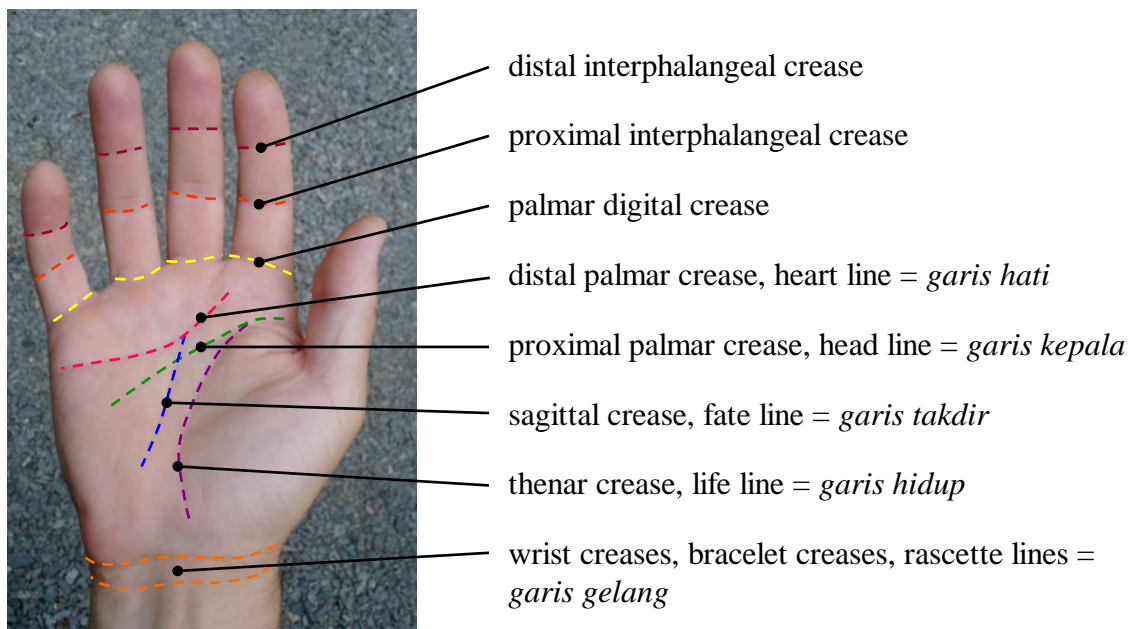
34. bend of the elbow, recess of the elbow = *leungkungan siku*. Colloquially it is also called the inside of the elbow.

35. funny bone = *tulang lucu, tulang siku yang peka*. The funny bone is actually the ulnar nerve (*saraf ulnaris*) where it passes around the back inside of the elbow in a shallow groove known as the cubital tunnel (*terowongan kubital*). Striking this nerve can result in a sharp tingling sensation (*perasaan kesemutan tajam*) that runs down the forearm into the ring and pinky fingers.

36. hollow of the hand = *lekuk tangan*. This is the depression formed in the palm when the hand is cupped.

37. palmar creases, palmar flexion creases, lines in the palm of the hand = *rajab tangan, urat tangan, retak di telapak tangan, lipatan-lipatan garis tangan*.

In palmistry lines in the palm are individually named. While one can find references to palm reading (*membaca garis tangan*) in the Indonesian context, it appears to me, at least from a cursory web search, that concepts associated with palm reading have been borrowed from the West. Nonetheless, in case it may prove significant to your research here are the names of some of the prominent fold lines of the hand.



Other fold lines (not highlighted) carry names such as marriage line, Venus line, Mars line, and sun line.

## Legs and feet

**38.** gluteal folds = *lipatan bokong*. These are folds on one's backside where the buttocks meet the thigh.

**39.** fold of the thigh = *lipatan paha*. There are two creases, left and right, where the torso meets the thighs. The V-shape made by these folds defines the groin area (*selangkang, selangkangan, kunci paha*).

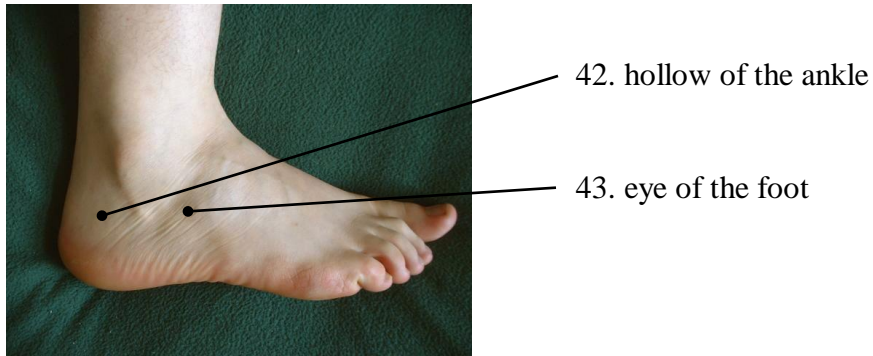
**40.** crotch, perineum, the area between the legs where they join the body = *kerampang, perineum, daerah antara lubang dubur dan bagian alat kelamin*. The perineum is the area extending from the anus to the genitals. The crotch is similar, but is usually considered to include the groin and the genitals. The Indonesian term *kelangkang*, also *celah kangkang*, properly refers to the V-shape opening formed by the thighs when the legs are open—cf. *mengangkang* 'stand, sit, etc. with the legs apart'—but is sometimes also understood to refer to the crotch or groin.

**41.** popliteal space = *lipatan lutut, pelipatan lutut*. Colloquially this is known as the back of the knee, or space or hollow in back of the knee. It is also called the bend or ham of the knee.

In Ledo the word for 'back of the knee' is *kente*, and it is also used in their equivalent to foothills, i.e. 'the back of the knee of the mountain' (Donna Evans 2010:pers.comm.).

**42.** hollow of the ankle, depression between the Achilles tendon and the bony protuberance of the ankle (malleolus) = *lekuk antara urat keting dan mata kaki*. In fact two hollows can be distinguished, the inner hollow of the ankle on the inside of the foot (behind the medial malleolus, that is, the lower extremity of the tibia or shinbone), and the outer hollow of the ankle on the outside of the foot (behind the lateral malleolus, the bottom end of the fibula).

**43.** sinus tarsi region, eye of the foot = *lekuk antara tulang tumit dan tulang talus*. The eye of the foot is a surface depression on the outside front of the ankle. It lies above a small cavity or canal, called the sinus tarsi, that lies between the ankle bone (talus) and the heel bone (calcaneus), just in front of the bony protuberance of the fibula (lateral malleolus). Passing through the sinus tarsi are various anatomical structures including ligaments. Because of this, this area—usually a slight depression—may swell following an ankle sprain.



Public Domain (Wikimedia).

The Indonesian term *mata kaki* refers not to this depression but rather to the bony protuberances of the ankle (malleoli), *tonjolan bulat pd kiri kanan pergelangan kaki*.

## References

Stevens, Alan M.; and A. Ed. Schmidgall-Tellings. 2004. *A comprehensive Indonesian-English dictionary*. Athens, OH: Ohio University Press.

Tim Penyusun Kamus Pusat Pembinaan dan Pengembangan Bahasa. 2001. *Kamus besar bahasa Indonesia*, 3rd edition. Jakarta: Balai Pustaka.

## Appendix: Bones of the body

Since an investigation of notches and hollows may lead to a discussion of skeletal structure, in this appendix I include a checklist of bones of the body. It is drawn from the third edition of *Kamus Besar Bahasa Indonesia*, from Stevens and Schmidgall-Tellings's *A Comprehensive Indonesian-English Dictionary*, and from various internet sources including "Daftar tulang pada rangka manusia."<sup>5</sup> Latin terms are included in the right-most column as these are sometimes incorrectly cited on Indonesian-language websites.

Note the following ambiguities:

The Indonesian term *tulang lidah* can refer to the vomer bone or the hyoid bone.

The Indonesian term *tulang leher* can refer to the cervical vertebrae or to the collarbone.

The Indonesian term *tulang pungkur* can refer to the lumbar vertebrae or the pubic bone.

skull	tengkorak, tulang kepala	cranium
braincase, brainpan	tempurung kepala	neurocranium
frontal bone	tulang dahi	os frontale
ridge of the brow, supraorbital ridge, superciliary arch	tulang tutup dahi	arcus superciliaris
parietal bone	tulang ubun-ubun	os parietale
occipital bone	tulang kepala belakang	os occipitale
temporal bone	tulang pelipis, tulang tudung	os temporale
sphenoid bone	tulang baji	os sphenoidale
ethmoid bone	tulang tapis	os ethmoidale
facial bones	tulang muka	ossa faciei, ossa facialia
cheekbone, malar bone, zygomatic bone	tulang pipi, tulang bercagak, tulang pengancing	os zygomaticum, zygoma
lacrimal bone	tulang air mata	os lacrimale

<sup>5</sup> *Wikipedia Ensiklopedia Bebas*, [https://id.wikipedia.org/wiki/Daftar\\_tulang\\_pada\\_rangka\\_manusia](https://id.wikipedia.org/wiki/Daftar_tulang_pada_rangka_manusia) (accessed May 15, 2017).

nasal bone	tulang hidung	os nasale
cartilage of the nose, septal nasal cartilage	tulang lunak hidung, tulang muda hidung	cartilago septi nasi
palate bone, palatine bone	tulang langit-langit	os palatinum
upper jawbone, maxilla	tulang rahang atas	maxilla
jawbone, mandible	tulang rahang, tulang rahang bawah	mandibula
alveolar process, alveolar bone	tulang ceruk	processus alveolaris
mandibular condyle, condyloid process, condylar process	tulang keng	processus condylaris mandibulae
vomer bone	tulang lidah	vomer
hyoid bone	tulang lidah, tulang merah	os hyoideum
bones of the inner ear, auditory ossicles	tulang dengar, tulang pendengaran, tulang-tulang	ossicula auditus, ossicula auditoria
hammer	tulang martil	malleus
anvil	tulang landasan	incus
stirrup	tulang sanggurdi	stapes
shoulder girdle, pectoral girdle	tulang gelang bahu	cingulum pectorale
collarbone, clavicle	tulang selangka, tulang cenak, tulang leher	clavicula
shoulderblade	tulang belikat, tulang kipas, tulang dayung, tulang lembusir, tulang papan bahu	scapula
summit of the shoulder, acromion	tulang ujung belikat	acromion
rib cage	sangkar rusuk	cavea thoracis
breastbone	tulang dada, tulang papan, tulang rimau menangis	sternum
manubrium	kepala tulang dada	handle
body of the sternum	badan tulang dada	gladiolus

xiphoid process	tulang sudu hati, tulang hulu hati, tulang caping, taju pedang	processus xiphoideus
ribs	tulang rusuk, tulang iga	costae
fixed ribs, true ribs	tulang rusuk sejati	costae verae
false ribs	tulang rusuk palsu	costae spuriae
floating ribs	tulang rusuk melayang	costae fluitantes
backbone, spine	tulang belakang	columna vertebralis
vertebrae (singular: vertebra)	ruas tulang belakang	vertebrae (singular: vertebra)
cervical vertebrae	tulang leher	vertebrae cervicales
thoracic vertebrae	tulang punggung	vertebrae thoracicae
lumbar vertebrae	tulang pinggang, tulang pungkur	vertebrae lumbales
sacrum	tulang kelangkang	os sacrum
tailbone, coccyx	tulang ekor, tulang tongkeng, tulang tungging, tulang kongkeng, tulang cenonot, tulang sulbi	os coccygis
pelvic girdle	tulang gelang panggul	cingulum pelvicum
pelvic bone, hip bone	tulang pinggul, tulang panggul	os coxae, os innominatum
ilium	tulang pukang, tulang pinggul atas, tulang usus	os ilium
crest of the ilium, iliac crest	tulang kelek buyung	crista iliaca
ischium	tulang duduk, tulang pantat	os ischii
pubic bone	tulang kemaluan, tulang pungkur, tulang som	os pubis
arm bones	tulang lengan	ossa membri superioris
humerus, upper arm bone	tulang lengan atas, tulang pangkal lengan, tulang kucing	humerus

radius	tulang pengumpul	radius
ulna	tulang hasta	ulna
hand bones	tulang tangan	ossa manus
wrist bones, carpal bones	tulang pergelangan tangan, tulang karpal	ossa carpi
scaphoid bone	tulang biduk	os scaphoideum, os naviculare manus
lunate bone, semilunar bone	tulang bulan, tulang bulan sabit	os lunatum
triquetral bone, pyramidal bone, three-cornered bone, triangular bone	tulang segitiga	os triquetrum, os pyramidale, os triangulare
pisiform bone	tulang kacang	os pisiforme
trapezium, greater multangular bone	tulang besar segi banyak	os trapezium, os multangulum majus
trapezoid bone, lesser multangular bone	tulang kecil segi banyak	os trapezoideum, os multangulum minus
capitate bone	tulang berkepala	os capitatum, os magnum
hamate bone, unciform bone	tulang berkait	os hamatum
hand bones	tulang telapak tangan	ossa metacarpalia
finger bones, phalanges (singular: phalanx bone)	tulang jari tangan	phalanges manus (singular: phalanx manus)
knuckles	buku jari, tulang ketuk jari	articuli digitorum
leg bones	tulang tungkai, tulang kaki	ossa membri inferioris
thigh bone, femur	tulang paha, tulang pangkal paha	os femoris, os longissimum
kneecap	tulang tempurung lutut. cawan-cawan lutut, cencawan, kunci lutut	patella
shinbone	tulang kering	(os) tibia
calf bone	tulang betis	(os) fibula



malleolus (plural: malleoli)	tulang buku lali, tonjolan buku lali, tulang alah mak, tulang mata kaki, tulang mata duli	malleolus, malleoli
foot bones	tulang kaki	ossa pedis
tarsus	tulang pergelangan kaki	ossa tarsi
heel bone	tulang tumit	calcaneus, calcaneum, os calcis
ankle bone, talus bone, astragalus	tulang talus	os trigonum, astragalus
cuboid bone	tulang kubus, tulang kuboid	os cuboideum
navicular bone	tulang kekura kaki	os naviculare
cuneiform bones	tulang runcing	ossa cuneiformia
foot bones, metatarsals	tulang telapak kaki	ossa metatarsalia
toe bones, phalanges (singular: phalanx bone)	tulang jari kaki	phalanges pedis (singular: phalanx pedis)